

博士學位論文

spatiotemporal image correlation 法による
妊娠中期の胎児心臓スクリーニングについて

近畿大学大学院医学研究科

医学系発達小児医学

高 田 の り

Doctoral Dissertation

Second-trimester fetal heart screening using the
spatiotemporal image correlation method

November 2018



Department of Pediatrics, Major in Medical Sciences
Kindai University Graduate School of Medical Sciences

Nori Takada

同意書

平成30年10月25日

近畿大学大学院
医学研究科長 殿

共著者	<u>杉本 志 翔</u>		共著者	<u>稲 下 昇</u>	
共著者	_____	Ⓜ	共著者	_____	Ⓜ
共著者	_____	Ⓜ	共著者	_____	Ⓜ
共著者	_____	Ⓜ	共著者	_____	Ⓜ
共著者	_____	Ⓜ	共著者	_____	Ⓜ

論文題目

Second-trimester fetal heart screening using the spatiotemporal image correlation method

下記の学位論文提出者が、標記論文を貴学医学博士の学位論文（主論文）として使用することに同意いたします。
また、標記論文を再び学位論文として使用しないことを誓約いたします。

記

- 学位論文提出者氏名 高田 のり
- 専攻分野 医学系 発達小児医学

Second-trimester fetal heart screening using the spatiotemporal image correlation method

Nori Takada, Keisuke Sugimoto, Noboru Inamura

Department of Pediatrics,
Kindai University Faculty of Medicine

Abstract

Background: The spatiotemporal image correlation (STIC) method, an echocardiographic approach to collecting data for offline analysis, can be used to perform fetal heart screenings. However, the utility of this technique for this indication is unknown.

Method: We screened and analyzed the STIC data for all normal pregnancies ($n = 405$) at 2 obstetrics clinics in Osaka from January 2017 through June 2018. An obstetrician and a laboratory technician collected the STIC data from a four-chamber view image. A pediatric cardiologist analyzed the data offline. The images analyzed included the four-chamber view, pulmonary veins, right and left outflow view, three-vessel view, and three-vessel trachea view. We classified findings of each image as normal, abnormal, or unconfirmed, and evaluated the final diagnoses.

Results: There were 324 normal cases (80.0%), 25 abnormal cases (6.2%), and 56 unconfirmed cases (13.8%). Eleven patients had congenital heart disease (CHD) after birth; of these, 9 had severe CHD requiring hospitalization. The sensitivity and specificity of the STIC method for detecting CHD was 100% and 95.9%, respectively.

Conclusion: The STIC method was useful for performing fetal CHD screenings. However, many images could not be analyzed.

Key words : fetal echocardiography, telemedicine, fetal diagnosis, congenital heart disease

Introduction

Congenital heart disease (CHD) affects 3-8 per 1000 live births¹. However, the incidence of CHD in aborted and stillborn infants is 5 times that of live-born infants. Therefore, it is considered to be more prevalent in fetuses². Fetal heart screenings are important because 90% of CHD cases begin during gestation in the absence of clear risk factors³. The spatiotemporal image correlation (STIC) method involves collecting short-term (5-15 sec) data from a four-chamber view obtained during echocardiography for offline analysis. The purpose of this prospective study was to calculate the sensitivity and specificity of the STIC method for fetal heart screening tests and examine its utility and potential drawbacks.

Material and Method

We obtained the STIC data once for each pregnant woman (n = 405; 19–35 gestational weeks [median 26 weeks]) who visited the offices of one of two obstetricians -(Department of Obstetrics and Gynecology Taniguchi Hospital, Kasamatsu Obsterics and Gynecology) in our hospital neighborhood between January 2017 and June 2018.

We explained the “right to know” and the “right not to know” concepts to subjects before the commencing screening tests. Furthermore, we explained the purpose of the screening tests and obtained informed consent from each subject.

The study protocol was approved by the Ethics Review Board of Kindai University (RH28-07)

Heart screening using the STIC method

We used the Voluson E8 and E10 ultrasound systems (GE Healthcare Japan, Tokyo, Japan) to perform fetal heart screening. A trained laboratory technician or obstetrician performed the screening during a routine obstetric examination.

First, we obtained a four-chamber view image and collected the STIC data comprising approximately 10-40 heartbeats (5–15 s). Next, we transferred the STIC data via a virtual private network line. The transferred data were rebuilt as an image on a personal computer by a View PAL system (GE Healthcare Japan, Tokyo, Japan). In the STIC image display, the cross-section (section A) on the upper left, which is the main part, is a normal B mode tomogram and the cross-section on the upper right (section B) rotates the probe in the A section 90° counterclockwise. At the same time, a cross-sectional image parallel to the base surface is displayed on the lower left section (C section). Sections B and C are displayed by reconstruction of the image by mathematic calculation algorithms. It is possible to rotate around three mutually orthogonal axes or translate it and obtain an arbitrary tomogram of the collected data (Figure 1).

A pediatric cardiologist (N.I.) analyzed the rebuilt images.

The analyses confirmed the following points sequentially (Table 1) :⁴

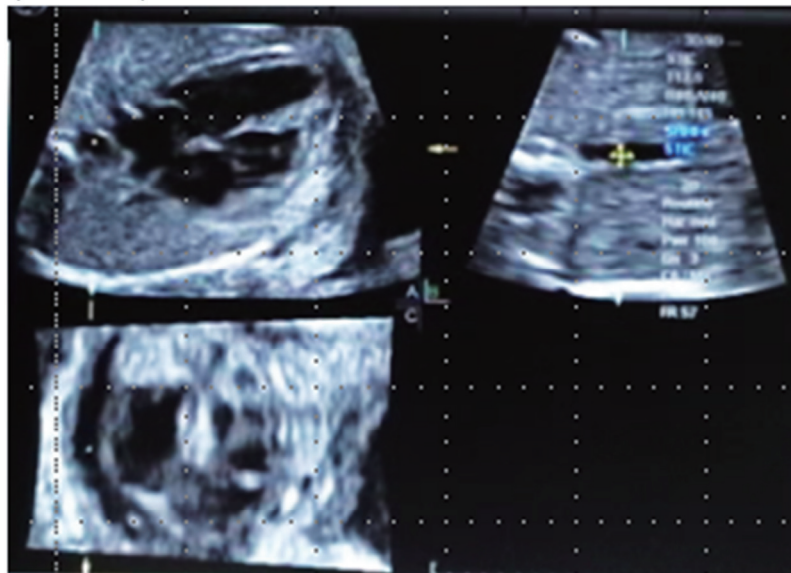
- 1) Abdominal cross-section: position of the fetal apex of the heart and the stomach;
- 2) Four-chamber view: heart size, laterality, heart axis, ventricular septum, and connection of the pulmonary

vein to the left atrium;

- 3) Left and right outflow tract view: size of the great vessels and crossing over of the great vessels;
- 4) Three-vessel view: major vascular balance and position; and
- 5) Three-vessel trachea view: size of the aortic arch and the ductal arch and the bloodstream direction.

We confirmed each image point in the evaluation and classified the analysis results as normal, abnormal, or unconfirmed. The analysis method is based on “fetal echocardiography guidelines” Level I and II.⁵ A second examination was conducted by a pediatric cardiologist in cases in which the analytical results were abnormal. Neonates with suspected CHD within 1 month after birth were identified as having CHD, while those with CHD that required hospitalization and treatment within 1 month after birth were identified as having severe CHD.

Figure1: STIC images (normal case)



upper left: section A, upper right: section B, lower left: section C

Figure 1. Spatiotemporal image correlation images (normal case)

Table1. Heart screening checklist

Section	Check item		
Upper abdomen View			
Position of stomach and apex	<input type="radio"/> Same ,	<input type="radio"/> Opposite,	<input type="radio"/> Unconfirmed
Four-chamber View	<input type="radio"/> Normal,	<input type="radio"/> Abnormal,	<input type="radio"/> Unconfirmed
Heart size			
Cardiac axis			
Balance of both ventricles			
ventricular septum			
Pulmonary vein	<input type="radio"/> Normal,	<input type="radio"/> Abnormal,	<input type="radio"/> Unconfirmed
Left ventricular outflow view	<input type="radio"/> Normal,	<input type="radio"/> Abnormal,	<input type="radio"/> Unconfirmed
Right ventricular outflow view	<input type="radio"/> Normal,	<input type="radio"/> Abnormal,	<input type="radio"/> Unconfirmed
Three vessels view	<input type="radio"/> Normal,	<input type="radio"/> Abnormal,	<input type="radio"/> Unconfirmed
Three vessels trachea view	<input type="radio"/> Normal,	<input type="radio"/> Abnormal,	<input type="radio"/> Unconfirmed
Analysis results	<input type="radio"/> Normal,	<input type="radio"/> Abnormal,	<input type="radio"/> Unconfirmed

Results

Of the 405 prenatal diagnoses, 324 (80.0%) were classified as normal, 25 (6.2%) as abnormal, and 56 (13.8%) as unconfirmed.

The detection rate by view was 98.3% for the four-chamber, 92.1% for the right and left outflow, 88.1% for the three-vessel, 83.0% for the three-vessel trachea, and 84.4% for the pulmonary vein views (Figure 2). The 95% confidence intervals were calculated using the exact method based on binomial distribution.

Table 2 shows the pre- and postnatal diagnosis results of CHD using the STIC method. Among the 324 patients with a normal prenatal diagnosis, none were diagnosed with CHD postnatally (i.e., a false-negative rate of 0%). In contrast, we diagnosed 14 normal heart cases postnatally among 25 cases of abnormal prenatal diagnosis (i.e., a false-positive rate of 56.0%); of these, a ventricular septal defect (VSD) was identified in 6. The sensitivity and specificity of the STIC method for CHD screening was 100% and 95.9%, respectively.

Table 3 shows the postnatal CHD diagnosis results. A total of 11 infants had CHD, 2 had VSD with a small defect not requiring hospitalization, and 9 had severe CHD requiring hospitalization. There were 2 cases each of Tetralogy of Fallot, a double-outlet right ventricle, and a double aortic arch. There was 1 case each of Ebstein anomaly, hypoplastic left heart anomaly, and total anomalous pulmonary venous connection. Other cardiac abnormalities including great vessel abnormality were noted in 3 cases. These findings show that fetal heart screening using the STIC method was able to detect congenital heart diseases with high efficiency and accuracy.

Figure 2: detection rate by telemedicine of STIC method

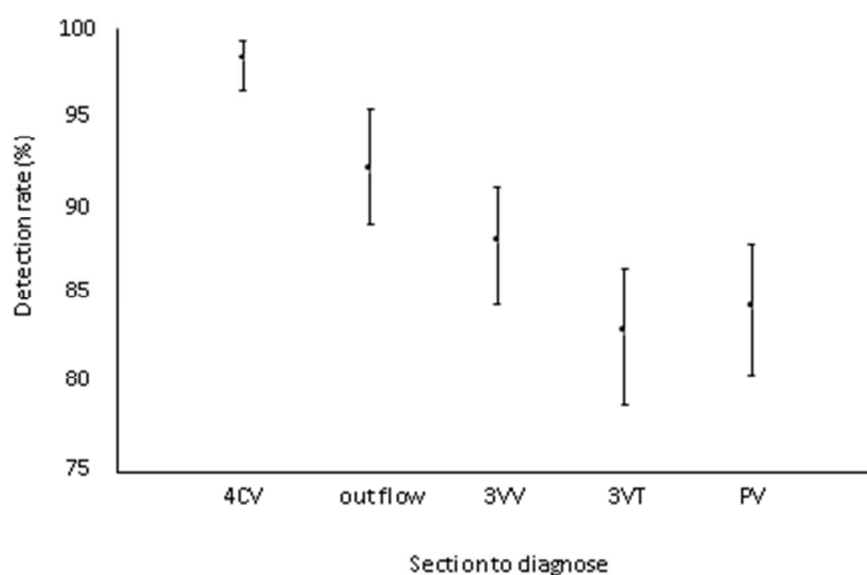


Figure 2. Detection rate by telemedicine using the spatiotemporal image correlation method
 D 4CV, four-chamber view; 3VV, three-vessel view; 3VT, three-vessel trachea view;
 PV, pulmonary vein

Table 2. Results of CHD

Fetal diagnosis \ Neonatal diagnosis	Normal	Abnormal	
CHD (+)	0	11	11
CHD (-)	324	14	338
	324	25	349

Sensitivity of CHD : $11/11 = 100\%$

Specificity of CHD : $324/338 = 95.9\%$

Table 3. Details of congenital heart defect (n = 11) confirmed postnatally

Septal defects	
Ventricular	2
Atrioventricular	0
Conotruncal anomalies	
Transposition of the great arteries	0
Tetralogy of Fallot	2*
Double-outlet right ventricle	2*
Truncus arteriosus	0
Right heart anomalies	
Hypoplastic	0
Pulmonary atresia with intact ventricular septum	0
Pulmonary stenosis	0
Ebstein anomaly	1*
Left heart anomalies	
Hypoplastic	1*
Aortic coarctation	0
Aortic arch interruption	0
Complex congenital heart defects	
Single ventricle	0
Other anomalies	
Double aortic arch	2*
Total anomalous pulmonary venous connection	1*
Congenital diaphragmatic hernia	0
Hypoplastic right lung	0

* Severe congenital heart disease requiring hospitalization

Discussion

The utility of telemedicine in the diagnosis of fetal heart disease was recently reported.⁶⁻⁹ Here, we prospectively examined the usefulness of the STIC method for fetal heart screening. Of the images included in this study, 14% could not be analyzed. This, of course, is the main disadvantage of the STIC method. Its detection rate varies depending on the different characteristics of the mothers, including obesity and presence of polyhydramnios and oligohydramnios, and fetuses, including presentation, size, and presence of hydrops, characteristics.^{6,10} These were the reasons that we could not analyze a subset of the images. Short screening

times result in little influence of fetal movements. The Voluson E10 can complete screening within 5 seconds. Thus, as the use of the Voluson E10 becomes more popular, we can expect to see a concomitant reduction in the rate of unconfirmed diagnoses.

However, it is difficult to increase the diagnosis rate of VSD without increasing image resolution. This is one of the drawbacks of the STIC method. Another drawback is that the detection rate differs for the images taken from different views. The detection rate with the four-chamber view was 98.3%, while that with the three-vessel trachea view was 82.9%. The STIC data included approximately 10–40 heartbeats (5–15 sec). After loading the four-chamber view, we collected the STIC data. For this reason, the detection rate with the four-chamber view, which was scanned first, was high, whereas that of the three-vessel trachea view, which was scanned last, was low. Fetal respiration and body movements influenced the detection rate despite the short data collection time.⁶ We think that the aforementioned problems can be solved by further shortening the scanning time.

According to our study, the sensitivity and specificity rates of the STIC method for detecting CHD were 100% and 95.9%, respectively. The STIC method is useful for screening for CHD. Our method was performed by obstetricians and ultrasound technicians using only the four-chamber view and a cardiologist analyzed the images. For this reason, no expert knowledge or special training is required for obstetricians or ultrasound technicians.⁷ In other words, screening can once the device becomes available. The rate of false-positive VSD diagnosis was high with this technique. We believe that the spontaneous closure of the VSD at birth could be a reason for this finding.¹¹

The high specificity of 95.9% can be attributed to the fact that the pediatric cardiologist was able to use multiple views to arrive at a diagnosis. Because there were no false-negative cases, our method is suitable for cardiac screening. Severe CHD is aggravated after birth. Complete transposition of the great arteries, total anomalous pulmonary venous drainage, and coarctation of the aorta are representative of CHD that worsens in the neonatal period.^{12, 13} These conditions appear normal in the four-chamber view. Thus, making a diagnosis based on a four-chamber view is difficult. A report from the Nevada State Clark County concluded that the sensitivity of screening using only the four-chamber view, was 36%. However, the sensitivity increased to 71% when the right and left ventricular outflow views were included.¹² The sensitivity of the CHD screening described here also improved if a second view was added.^{12, 14} However, the detection rates varied with the use of different views. The detection rate with the four-chamber view was 98.3%. The detection rate using views other than the four-chamber was high using the STIC method as well. The detection rate using the right and left outflow view was 92%; three-vessel view, 88%; and three-vessel trachea view, 83%. Our method had higher detection rates than the traditional four-chamber view because a specialist made the diagnoses. Therefore, a double aortic arch could be screened. The STIC method, that can easily receive expert diagnosis is useful for CHD.

Study limitation

In this study, several echocardiographic laboratory technicians and obstetricians collected images that were analyzed by a single cardiologist. Because there was only 1 analyst, there were no inter-analyst differences. This fact may have influenced the sensitivity and specificity of the study. In a future study, we will include multiple examiners and examine the differences in their diagnoses.

Conclusion

In this study, we attempted to diagnose prenatal CHD using the four-dimensional STIC method in 405 pregnant women who underwent fetal heart screening at an obstetrics and gynecology department. A total of 56 cases (13.8%) could not be analyzed. There were 14 false-positive and 0 false-negative diagnoses. The sensitivity and specificity of the STIC method for identifying CHD were 100% and 95.9%, respectively. Thus, our data suggest that the STIC method is useful for screening for fetal CHD.

Acknowledgement

The authors express gratitude to Yasutaka Chiba, PhD (Clinical Research Center, Kindai University Hospital, Osaka, Japan) for his useful comments.

Conflicts of interest

The authors declare no conflicts of interest.

Reference

1. Allan L, et al (2001) Isolated major congenital heart disease. *Ultrasound Obstet Gynecol* 17:370-379.
2. Smythe JF, Copel JA, Kleinman CS (1992) Outcome of prenatally detected cardiac malformations. *Am J Cardiol* 69:1471-1474.
3. Achiron R, Glaser J, Gelerntter I, Hegesh J, Yagel S (1992) Extended fetal echocardiographic examination for detecting cardiac malformations in low risk pregnancies. *BMJ* 304:671-674.
4. ISUOG. (2013) ISUOG Practice Guidelines (updated):sonographic screening examination of the fetal heart. *Ultrasound Obstet Gynecol* 41:348-359, 2013
5. Fetal heart echocardiography guideline creation committee. (2006) Fetal echocardiography guidelines. *Ped Cardiol Card Surg* 22 (5):591-613.
6. Zhao L, et al. (2016) Feasibility study on prenatal cardiac screening using four-dimensional ultrasound with spatiotemporal image correlation:a multicenter study. *PloS ONE* 11 (6):e0157477.
7. Bennasar M, et al. (2010) Accuracy of four-dimensional spatiotemporal image correlation echocardiography in the prenatal diagnosis of congenital heart defects. *Ultrasound Obstet Gynecol* 36:458-464.
8. Juliana Y, et al. (2015) Screening of congenital heart diseases by three-dimensional ultrasound using spatiotemporal image correlation :influence of professional experience. *Echocardiography* 33:99-104.
9. Bennasar M, et al. (2009) Feasibility and accuracy of fetal echocardiography using four-dimensional spatiotemporal image correlation technology before 16 weeks' gestation. *Ultrasound Obstet Gynecol* 33:645-651.
10. De Vore G, et al. (1993) Fetal echocardiography:factors that influence imaging of the fetal heart during the second trimester of pregnancy. *J Ultrasound Med* 12:659-663.
11. Mosimann B, Zidere V, Simpson JM, Allan LD. (2014) Outcome and requirement for surgical repair following prenatal diagnosis of ventricular septal defect. *Ultrasound Obstet Gynecol* 44 (1):76-81.
12. Evans W, et al. (2015) Moving towards universal prenatal detection of critical congenital heart disease in southern Nevada:a community-wide program. *Pediatr Cardiol* 36:281-288.
13. Pinto NM, et al. (2012) Barriers to prenatal detection of congenital heart disease:a population-based study. *Ultrasound Obstet Gynecol* 40:418-425.
14. Carvalho JS, Mavrides E, Shinebourne EA, Campbell S, Thilaganthan B. (2002) Improving the effectiveness of routine prenatal screening for major congenital heart defects. *Heart* 88:387-391.

